Indications

Chest pain in patient with cardiac history or of possible cardiac origin. Shortness of breath, abdominal pain, shoulder pain, arm or neck pain in diabetics or recreational stimulant users and patients over 50 years old.

Precautions

DO NOT DELAY DEFIBRILLATION IN V-FIB OR PULSELESS V-TACH TO OBTAIN 12 LEAD!

DO NOT DELAY CARDIOVERSION WITH UNSTABLE TACHYCARDIAS SUCH AS PSVT AND ATRIAL FLUTTER!

AVOID UNNECCESSARY DELAYS IN TRANSPORT FOR THE PURPOSE OF 12-LEAD EKG

Technique

1. Expose patient's chest and shave V-lead locations if hair present.
2. Attach limb leads to limbs. White lead to right arm, black lead to left arm, red lead to left leg and green lead to right leg.
3. Attach precordial leads:
    - V1-fourth intercostal space to the right of the sternum.
    - V2-Fourth intercostal space to the left of the sternum.
    - V3-between V2 and V4.
    - V4-fifth intercostal space, left mid clavicular line.
    - V5-fifth intercostal space, between V4 and V6.
    - V6-fifth intercostal space, left mid axillary line.

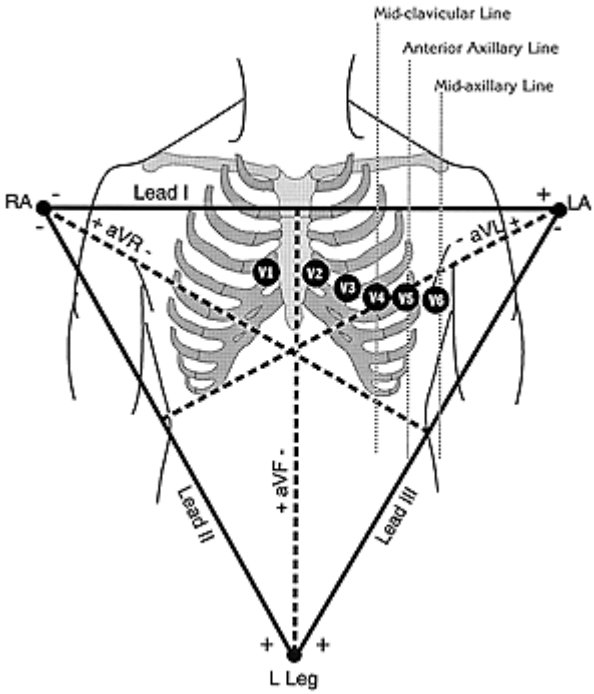

4. Push the 12-lead button; this will prompt you to enter the patient's age with the selector knob. 12-lead will print if tracing is clear. If tracing is not clear, check all leads and have patient lay still and have everyone else move back. Push the 12-lead button once more, the 12 lead will record and print.
5. After recording and printing EKG, determine course of action and treatment, including timely transport. Some history or EKG findings may warrant the use of alternate lead placements, i.e. V4r, posterior leads, etc.
6. Provide ED charge nurse a patient report and obtain necessary medication orders from the doctor.

Notes

1. A negative 12 lead does not rule out MI or other cardiac problems.
2. Do not delay transport to obtain EKG; however, there is usually time to obtain it while arranging transport into the ambulance.
3. Serial 12 leads can be valuable to show the evolution of pathology or the effect of treatments such as NTG.

4. NTG can substantially alter or eliminate ischemia patterns on EKG. When possible, obtain EKG's before treatment, as this information can be crucial to further treatment at the hospital.
5. Some monitors will display an interpretation on the printout. These are doubtful at best, and frequently completely wrong. Rely on your knowledge or advice from medical control. If you treat based on an interpretation that is different from that displayed on the printout, document your rationale carefully.
6. Reversal of the limb leads can give false results. Here are some fast ways to recognize a limb reversal:
    a. Flat line in any limb lead (I, II, III, aVR, aVL, aVF)
    b. aVR and V6 are not reciprocal
    c. P wave in I is larger than II, P wave in III is inverted or biphasic
7. Right ventricular MI does not usually appear in any of the normal leads. If a right ventricular MI is suspected, you may attempt a $V4_R$. Take the V4 lead and place it in the same location on the right side of the chest. ST elevation in this lead *may* indicate a right ventricular MI.
8. If you believe it is indicated and you are familiar with the landmarks, placement of alternate leads (i.e. V8, V9) can provide a more complete picture of an MI.